



PATIENT

Drogon Chauhan

SPECIES

Canine

BREED

Maltese Mix

SEX

MN

AGE

6yr

WEIGHT

NA

INTERPRETED BY

R. McKenzie Daniel,
DVM, DABVP
(Canine and Feline)

IMAGING PERFORMED BY

Meghan Morse

HOSPITAL NAME

Animal General
Hudson

REFERRING VET

Dr Zelinski

INVOICE

23904

DATE

02/16/2026

PRESENTING CLINICAL SIGNS

- Recheck splenic nodules, hx of bladder stones
- Current meds: C/d diet

ULTRASONOGRAPHIC EXAMINATION OF THE ABDOMEN

Urinary System

The urinary bladder, trigone, cystourethral junction, and visible pelvic urethra to a depth of 3 cm exhibited normal thickness and tone. Anechoic urine was present in the lumen with mild non-dependent particulate sediment. The ureteral papillae were normal. The ureters were not visible which is normal. No evidence of inflammatory or neoplastic changes was noted.

Normal size and margination were present in the kidneys. A normal 1:3 cortex / medulla ratio and normal corticomedullary definition were maintained. The echogenicity of the cortex was similar to or slightly less than normal liver parenchyma while the medulla echogenicity was hypoechoic to the cortex with no evidence of pelvic dilation. The left kidney measured 4.1 cm in length. The right kidney measured 4.0 cm in length.

The area of the aortic trifurcation was free of pathology.

Adrenal Glands

The left adrenal gland was uniform in size and contour with a uniformly hypoechoic parenchyma. The left adrenal gland measured 0.57 cm width at the caudal pole. The right adrenal gland was uniform in size and contour with a uniformly hypoechoic parenchyma. The right adrenal gland measured 0.43 cm width at the caudal pole.

Spleen

The spleen exhibited a finely textured and homogenous parenchyma which was hyperechoic to the liver and renal cortical parenchyma. The capsule was smooth and regular without apparent expansion. The splenic vasculature at the hilus was normal in volume with no evidence of congestion or thrombosis. Acute to chronic inflammatory, neoplastic, or benign parenchyma changes were not noted.

Liver/Gallbladder

The liver was subjectively normal in size, structure, and contour. The liver parenchyma was uniform and hypoechoic to the spleen with a mild coarse echotexture. Normal vascular volume. The hepatic and portal vasculature were normal in appearance without signs of congestion. The gallbladder was non-distended in size with thin walls and primarily anechoic luminal content. The cystic and common bile ducts were normal.

Gastrointestinal

The stomach presented intact wall layering with a normal wall layer ratio. The lumen of the stomach contained mild retained anechoic fluid with no signs of ileus, obstruction or foreign material.

The small intestine presented intact wall layering with 1:3 muscularis/mucosa ratio. The lumen of the small intestine was empty with no signs of mechanical/metabolic ileus, obstruction or foreign material.



PATIENT

Normal visible colon wall layers were present with apparent formed feces in lumen.

Drogon Chauhan

Pancreas

SPECIES

The parenchyma of the left limb, body and right limb of the pancreas presented isoechoic to the adjacent omental fat. A normal curvilinear capsule contour of the pancreas was present. The visible pancreatic duct was normal. No signs of active inflammation or neoplastic disease was evident.

Canine

Free Abdomen

BREED

No omental masses, overt lymphadenopathy or peritoneal effusion was present.

Maltese Mix

ULTRASONOGRAPHIC FINDINGS

Primary

SEX

- Sonographically normal spleen
- Normal urinary bladder with mild urine sediment

MN

AGE

INTERPRETATION OF THE FINDINGS & FURTHER RECOMMENDATIONS

6yr

No evidence of previously noted splenic nodules, as well as no evidence of urinary bladder mineral/calculi. The previously noted splenic nodules likely consistent with a resolved hematopoiesis or lymphoid hyperplasia. Correlation with UA +/- C/S if evidence of inflammatory sediment or UPC level if non-inflammatory proteinuria is recommended.

WEIGHT

NA

INTERPRETED BY

R. McKenzie Daniel,
DVM, DABVP
(Canine and Feline)

**IMAGING
PERFORMED BY**

Meghan Morse

HOSPITAL NAME

Animal General
Hudson

REFERRING VET

Dr Zelinski

**INVOICE
23904**

DATE
02/16/2026



PATIENT

Drogon Chauhan

SPECIES

Canine

BREED

Maltese Mix

SEX

MN

AGE

6yr

WEIGHT

NA

INTERPRETED BY

R. McKenzie Daniel,
 DVM, DABVP
 (Canine and Feline)

IMAGING PERFORMED BY

Meghan Morse

HOSPITAL NAME

Animal General
 Hudson

REFERRING VET

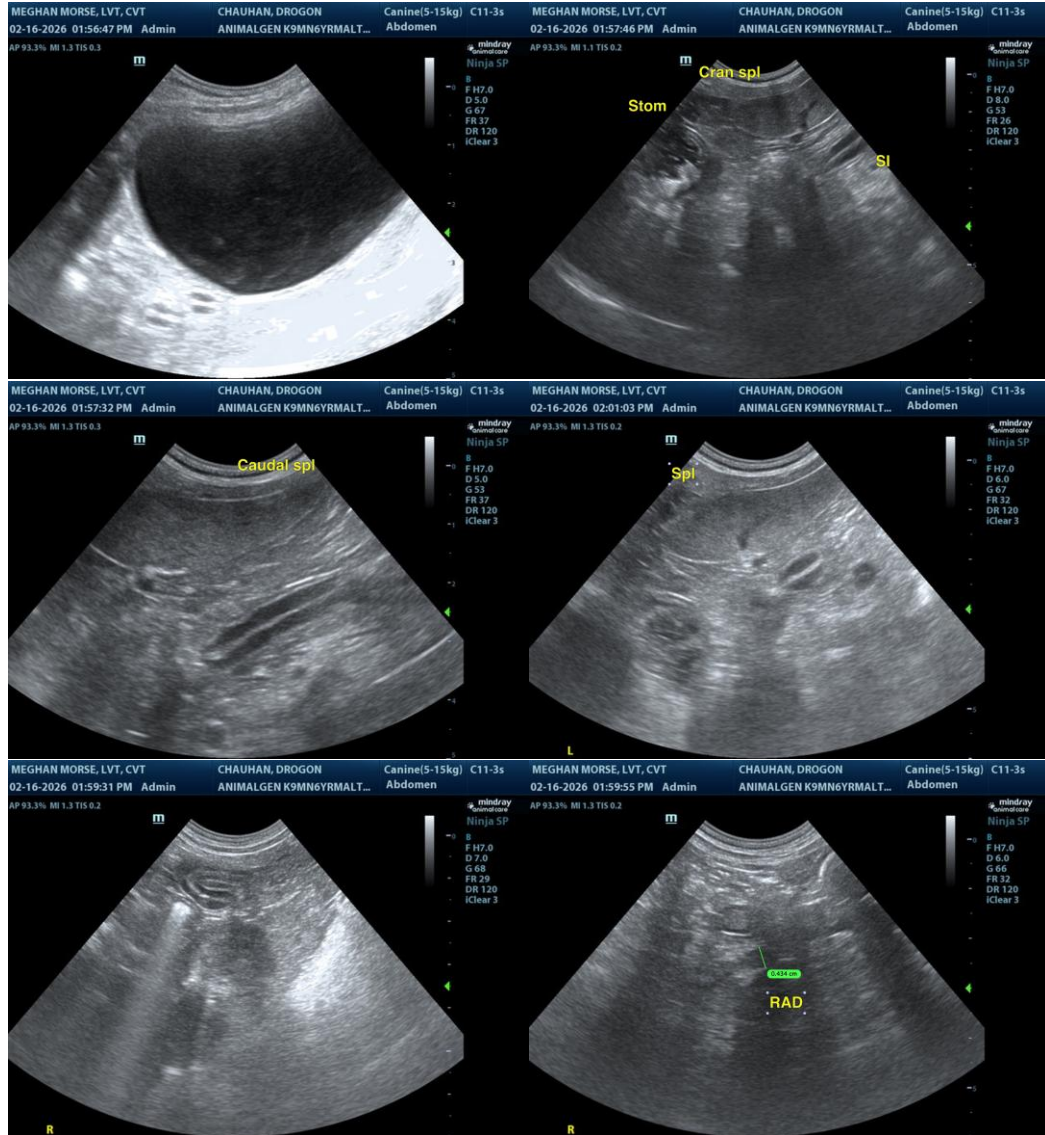
Dr Zelinski

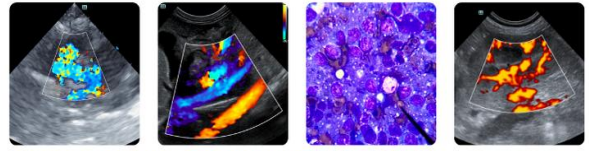
INVOICE

23904

DATE

02/16/2026





PATIENT

Drogon Chauhan

SPECIES

Canine

BREED

Maltese Mix

SEX

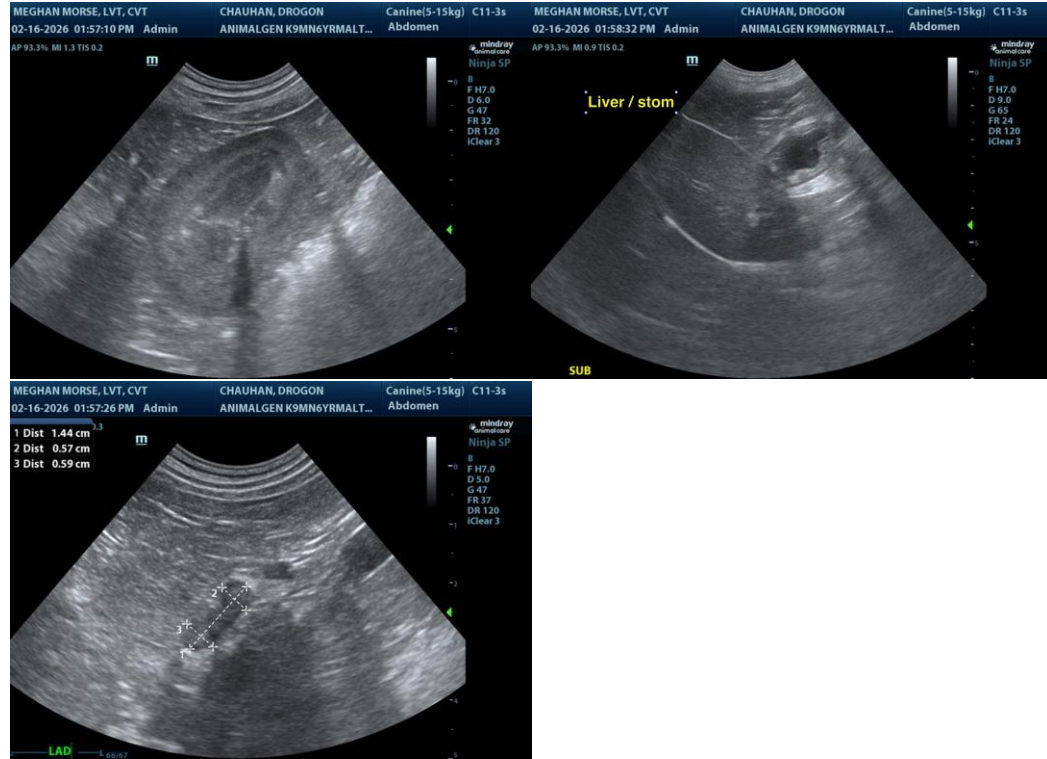
MN

AGE

6yr

WEIGHT

NA



INTERPRETED BY

R. McKenzie Daniel, DVM, DABVP
 (Canine and Feline)

The information and recommendations provided are based on the images presented by the referring veterinarian/sonographer. No evaluation can be communicated regarding pathology that was not visible in the image/video clips provided.

Thank you for this referral. If the clinical or image interpretation does not parallel your findings or if I can be of any further assistance, please contact me.

IMAGING PERFORMED BY

Meghan Morse

R. McKenzie Daniel, DVM, DABVP (Canine/Feline Practice)
info@sonopath.com

HOSPITAL NAME

Animal General Hudson

REFERRING VET

Dr Zelinski

INVOICE

23904

DATE

02/16/2026